



# Postnatal advancement of zygomatic organs from guinea pig: a morphological and morphometric examinations

Sanaya AR<sup>1</sup>, Antonio FA<sup>2</sup>, Robinho SF<sup>2</sup> and Romero FV<sup>2</sup>

<sup>1</sup>Department of Health Sciences, Federal University of Sao Paulo, UNIFESP, SP, Brazil. <sup>2</sup>Department of Biological Sciences, Bauru School of Dentistry, Sao Paulo University, USP, SP, Brazil.

## Abstract

The postnatal development of zygomatic glands from guinea pig (*Cavia porcellus*) ranging from 2 to 140 days of postnatal life was studied by means of morphological and morphometric methods. The results showed that the body weight growth has occurred in two phases from 2 to 7 and from 14 to 140 days. With respect to gland mass, its growth has also occurred in two phases from 2 to 7 and from 14 to 140 days of life. Regarding morphometric data of glandular components, the volume density of acini has decreased at 140 days of postnatal life when compared to other periods adopted in this study as depicted by significant statistically differences ( $p < 0.05$ ). Ducts showed an increase of volume density at 2, 14 and 21 days of postnatal life. The volume density of stroma increased progressively ( $p < 0.05$ ) at 140 days only. Taken together, we concluded that the morphofunctional development occurs in the zygomatic gland following 140 days of postnatal life evidenced by decrease in volume density of acini and ducts and the growth of the stroma.

**Keywords:** Zygomatic glands, development, guinea pig

## INTRODUCTION

The zygomatic glands are two exocrine units located on both sides of the head, between the dorsal- medial regions of the zygomatic arch, ventral region of the eyeball and lateral of the guinea pig masseter muscle (Cooper and Chiller, 1975). In several mammals' species such as dog, cat, rat, mouse, hamster and ferret, its description is similar (Kronman and Chauncey, 1964; O'Donnell and Huncey, 1968; Poddar and Jacob, 1977, 1978). According to some authors (Ballard, 1937; Dumas, 1953; Poddar and Jacob, 1977), the zygomatic glands arises as small excretory ducts that lead into the oral cavity in small papillae near the upper molar teeth. This description characterizes the zygomatic gland as a salivary gland (Kronman and Chauncey, 1964; Reifel and Travill, 1972; Poddar and Jacob, 1977, 1978; Mohr and Ernest, 1987). However, other studies have assumed the zygomatic gland as an extra orbital lachrymal gland, whose main duct leads into the orbital cavity (Quintarelli and Dellovo, 1964; Spicer and Duvenci, 1964; O'Donnell and Chauncey, 1968).

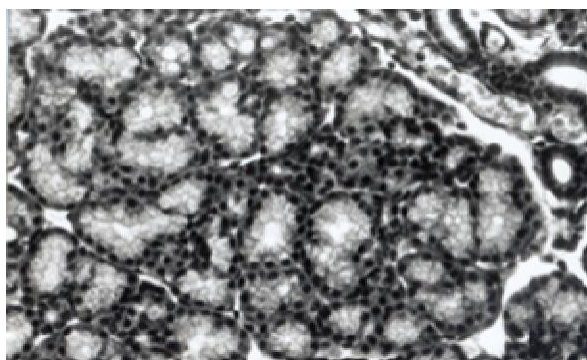
Independent of its presentation form, description of zygomatic gland from guinea pig through morphological

and morphometric methods is absent in literature. Herein, a evaluation of postnatal development of zygomatic gland is a necessary step to better establish this organ when studying morphogenesis, differentiation as well as morphological and functional maturation. As a result and because of inappropriate evidence, the goal of this study was to study postnatal development of zygomatic glands from guinea pig by means of morphological and morphometric methods.

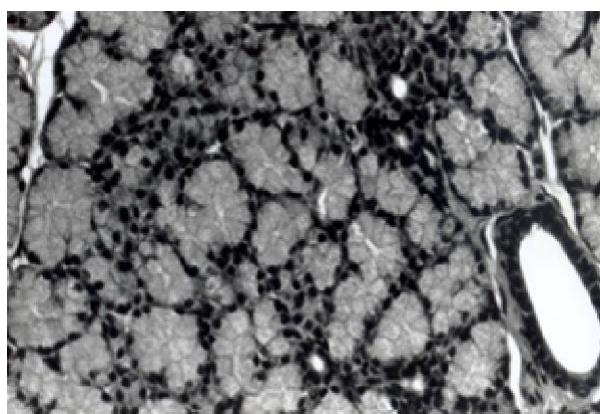
## MATERIALS AND METHODS

### Animals and experimental design

A total of 35 male guinea pigs (*Cavia porcellus*) were obtained from Biotério da Faculdade de Odontologia de Bauru - USP, SP, Brazil. All animals were housed in plastic cages with white chips for bedding (four guinea pigs per cage). Also, they were maintained under controlled conditions of temperature (24 °C), light-dark periods of 12 h, and with free access to water and commercial diet (Purina, SP, Brazil). The animals were randomized into groups of 5



**Figure 1.** Morphological aspects of guinea pig zygomatic gland at the 2nd day the little round acini show the nucleus of the little cells very close to each other. (H.E. stain, 480x)



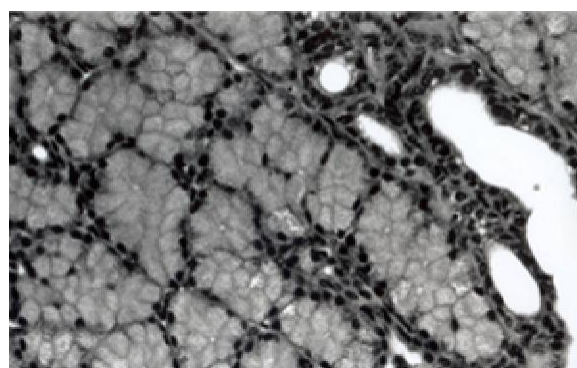
**Figure 2.** Morphological aspects of guinea pig zygomatic gland at the 14th day the acinar cells have increased in height and its cyto-plasm has a thicker secretion. Intercalated duct and excretory duct. (H.E. stain, 480x).

for the ages of 2, 7, 14, 21, 35, 70 and 140 days of postnatal life. These periods were chosen on the basis of previous study conducted by our group showing that a marked growth of glandular tissue from guinea pig occurs during the period from 2 to 70 days of post-natal life (Assis et al., 2003). The animals stayed with their mothers until the 21<sup>st</sup> day of life, when they were weaned.

Twelve hours before completing the experimental periods established, guinea pigs were submitted to fasting, then killed by intraperitoneal administration of 0.5 mL/kg body weight of xylazine plus (Agribands, USA) and 1.5 mL/kg body weight of Ketamine (Fort\_Dodge, Iowa, USA). After anesthesia, each animal had its body mass evaluated on a Mettler P1000 scale and registered in grams. The zygomatic glands were dissected for morphological examinations. After this, the zygomatic glands were dissected and their mass evaluated on a Mettler H-20 precision scale, and completed. The tissues were fixed in 10% buffered formalin (Merck, Darmstadt, Germany), and, embedded in paraffin blocks and stained with hematoxylin and eosin (H.E., Merck). The Animal Committee of the Bauru School of Dentistry, University of Sao Paulo (USP), approved all the experimental protocols.

#### Morphometric assessment

To confirm the interpretation of the morphological analysis in the zygomatic glands, a morphometric analysis was performed the details



**Figure 3.** Morphological aspects of guinea pig zygomatic gland at the 70th day the acini are expressively larger, with their cell nucleus very distant from each other. (H.E. stain, 480x).

of which, have been described previously (Weibel et al., 1970). Briefly, the density of the zygomatic gland acini, duct and stroma volume was set using a II Zeiss integration chart exhibiting 100 points and 10 parallel lines, contained in a focal plane of Kpl 8x ocular lens. The counting was done in an Olympus CH-2 microscope with 100x immersion objective. In 50 microscopic fields per animal, selected by systematic sampling (Weibel, 1970), the number of points about each gland structure (Pi) and about the gland (Pt) was registered. The volume density was calculated by the following relation:  $V_{vi} = Pi / Pt$  (Weibel, 1970).

#### Statistical methods

Comparisons of mean body weight, gland mass and volume density of all organelles evaluated among the groups were performed by one-way ANOVA followed by the post- hoc analysis (Tukey's test) for individual comparison.  $P < 0.05$  was considered statistically significant.

## RESULTS

### Morphological results

Figures 1, 2, 3 and 4 show photomicrographies from zygomatic glands at 2, 14, 70 and 140 postnatal life respectively. The 2 day-old glands are organized in lobes and lobules with small round acini, with very close nucleus. The septum stroma is represented by a loose conjunctive tissue (Figure 1). From this age on, stroma is progressively thicker and acinar cells increase in height and width until 70 days. In the 14th day, this increase is really apparent and the cytoplasm has more homogeneous optical density if compared to the acinar cells of younger animals (Figure 2). In the 70th day, acini are expressively larger, showing acinar cells with nucleus located in the basal portion and far from each other (Figure 3). In the 140th day, little difference in acini morphology is noticed, although they are larger than the ones observed in the 70th day. Furthermore, the septum stroma is composed by thicker conjunctive tissue, involving, mainly, the excretory ducts (Figure 4). The bigger diame-

**Table 1.** Evolution of the body weight, and gland mass from zygomatic gland of guinea pig following postnatal life.

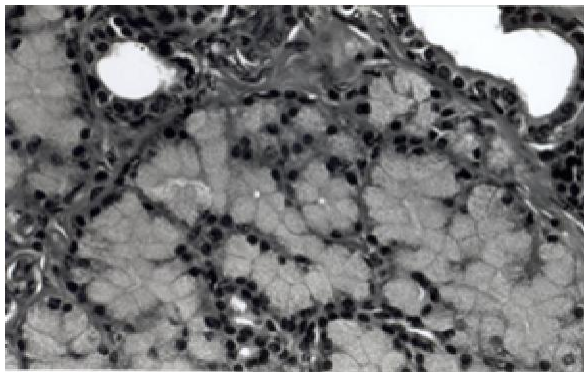
| Age in days            | 2                            | 7               | 14              | 21             | 35             | 70             | 140             |
|------------------------|------------------------------|-----------------|-----------------|----------------|----------------|----------------|-----------------|
| <b>Body Mass (g)</b>   | 113.10 ± 3.78 <sup>1,*</sup> | 146.00 ± 5.24*  | 162.50 ± 6.22** | 259.30 ± 13.31 | 324.50 ± 18.70 | 548.30 ± 18.00 | 813.80 ± 7.80** |
| <b>Gland Mass (mg)</b> | 138.76 ± 8.16*               | 185.12 ± 12.19* | 207.02 ± 9.33** | 274.30 ± 8.40  | 330.30 ± 20.10 | 530.80 ± 7.68  | 610.30 ± 6.74** |

<sup>1</sup>Values expressed as Mean ± Standard error. \*,\*\*p<0.05

**Table 2.** Mean standard deviation of volume density (%) of each gland component in the zygomatic gland of guinea pig following post natal life.

| Age in days   | 2                         | 7            | 14            | 21            | 35           | 70           | 140           |
|---------------|---------------------------|--------------|---------------|---------------|--------------|--------------|---------------|
| <b>Acini</b>  | 80.22 ± 0.13 <sup>1</sup> | 81.16 ± 0.87 | 81.08 ± 0.49  | 78.32 ± 0.79  | 77.42 ± 1.17 | 81.53 ± 0.79 | 74.27 ± 1.58* |
| <b>Ducts</b>  | 11.24 ± 0.76*             | 8.65 ± 0.90  | 11.23 ± 0.61* | 12.27 ± 0.87* | 8.61 ± 1.05  | 6.32 ± 0.40  | 6.07 ± 0.68   |
| <b>Stroma</b> | 8.55 ± 0.49               | 10.33 ± 0.39 | 7.71 ± 0.34   | 9.44 ± 0.18   | 14.24 ± 0.53 | 12.24 ± 0.68 | 19.67 ± 1.19* |

<sup>1</sup>Values expressed as Mean±Standard error. \*p<0.05.



**Figure 4.** Morphological aspects of guinea pig zygomatic gland at the 140th day the acini (A) are similar to the 70th day once and the septum stroma (S) shows a thicker conjunctive tissue. (H.E. stain, 480 x).

ter excretory ducts seem to be more frequent in higher ages. There were no morphological differences noticed in the intercalary duct at all periods from 2 to 140 days of postnatal life.

### Morphometric results

The evolution of body weight and, gland mass is presented in Table 1. The body weight growth has occurred in two phases from 2 to 7 and from 14 to 140 days, with increases, respectively, of 30% ( $p < 0.05$ ) and 400% ( $p < 0.05$ ). Between 7 and 14 days of postnatal life, no significant statistically differences ( $p > 0.05$ ) was detected. With respect to gland mass, its growth has also occurred in two phases from 2 to 7 and from 14 to 140 days of life. In these phases the percentage of increasing were respec-

tively, of 33% ( $p < 0.05$ ) and 195% ( $p < 0.05$ ).

Regarding morphometric data of glandular components, the volume density of acini has decreased at 140 days of postnatal life when compared to other periods adopted in this study as depicted by significant statistically differences ( $p < 0.05$ ). Ducts showed an increase of volume density at 2, 14 and 21 days of postnatal life. The volume density of stroma increased progressively ( $p < 0.05$ ) at 140 days only. All findings are summarized in Table 2.

### DISCUSSION

The zygomatic glands have been widely used in the histochemical study of polysaccharides and glycoproteins (Spicer and Duvenci, 1964; O'Donnel and Chauncey, 1968; Reifel and Travill, 1972; Poddar and Jacob, 1978). These studies were mainly done in carnivorous mammals (Reifel and Travill, 1972; Poddar and Jacob, 1978) and rodents (Spicer and Duvenci, 1964; Kronman et al. 1968). In these animals, zygomatic glands are located bilaterally in zygomatic arch regions near the ventral region of each eyeball. Although they form, in proportion, big exocrine secretory mass, their prenatal or postnatal morphological and functional development is almost unknown (Reifel and Travill, 1972). In the guinea pig, the zygomatic gland is very little referred, being the majority of published works ancient in literature (Spicer and Duvenci, 1964; Cooper and Schiller, 1975). The goal of this study was to evaluate the postnatal development of zygomatic glands in guinea pigs. To the best of our knowledge, the approach has not addressed so far. This justifies this study and others as well.

In the current research, the average 2-day-old guinea pig's body mass was 113.18 grams and 813.79 in the

140th day, presenting, therefore an increasing of 620% in this period. This increase becomes more evident from the 14th day on. Joekel et al. (1993) and Assis et al. (1996) earlier have also verified an evident increase on the guinea pig's body mass from the 15th day of postnatal life.

The zygomatic gland mass in the current research has increased 282% in the period between 2 to 70 days of postnatal life (~390 mg). On the other hand, the acini compartment volume did not increase in this same period evaluated. Furthermore, the volume density has decreased at 140 days of post-natal life. Taking into account these data and based on the assumption that acini occupy 79% of the gland mass, it is probable that the acini growth was the main factor for the gland increase in this period. This is fully in line with other authors that investigated the issue (Assis et al., 1996). This growth on the acini compartment absolute volume, and therefore on the gland mass, may have occurred because of an increase on the cell absolute number by proliferous activity and an increase on the cell individual volume. It is important to emphasize that the morphological analysis has showed a significant increase in the acinar cell volume in the period from 2 to 70-140 days. Probably, this was due to prolixiferous activity as the preponderant factor of the acinar compartment volume increase, and than the acinar cell volume also participates in this increase.

Microscopically, in any of the studied animals, the zygomatic gland presents a conjunctive tissue capsule able to organize into septum, dividing itself into irregular lobes and lobules. The secretory portion that is seen in the most part of the gland is represented by tubule-acinar structures, formed by mucous cells and in some of them with increasing or half-moon serous cell. From these structures, it is arisen rare and small interpolated ducts, that drain to the interlober and interlobular excretory ducts. Our results demonstrated an increase of ductal volume density ranging from two to 21 days of postnatal life. Nevertheless, this was not verified under microscopic analysis. Thus, this requires further study. The volume density of stroma increased at 140 days of postnatal life only. This finding was confirmed by microscopical evaluation. Therefore, we assumed that a proliferative activity of stroma cells starts at this experimental period.

Taken together, we concluded that the morphofunctional development occurs in the zygomatic gland following 140 days of postnatal life evidenced by decrease in volume density of acini and ducts and the growth of the stroma.

## REFERENCES

- Assis GF, Cestari TM, Sesso A, Taga R (2003) Post-natal maturation of acinal cells of the guinea pig pancreas: na ultrasctrutural morphometric study. *Anat. Histol. Embryol.* 32: 36-41.
- Assis GF, Stipp ACM, Barbosa FA, Taga R (1996). Estudo do crescimento do pâncreas da cobaia durante o período pós-natal. *Rev. Unimar. Ciencias.* 5: 4-11 (in Portuguese).
- Ballard OT (1937). The gross anatomy of cavia cobaya with a comparative study of another Hystoricomorph rodent, Erethizon dorsatus. Ph. D. Thesis, University of Kansas, in Cooper G; Schiller AL.(1975). p. 316.
- Cooper G, Schiller AL (1975). Anatomy of the guinea pig. Harvard University Press. Cambridge, Massachusetts. 304: 316- 317.
- Dumas J (1953). Les animaux de laboratoire. Éditions Médicales. Paris: Flammarion 10 - 27, in Cooper G; Schiller AL. (1975). p.316.
- Kronman JH, Chauncey HL (1964). Preliminary report of a fourth major salivary gland (zygomatic) in the hamster. *J. Dent. Res.* 43:1251.
- Kronman JH, O'Donnell LJ, Chauncey HH (1968). Morphologic and histochemical comparision of the zygomatic, lachrymal and sublingual glands in female golden hamster. *J. Dent. Res.* 47: 207-213.
- Mohr U, Ernst H (1987). Biology, care and use in research, in Van Hoosier, JR, GL; Mepherson, CW. Laboratory Hamsters, Academic Press, Inc. U.S.A. Chapter 20: 354.
- Poddar S, Jacob S (1977). Gross and microscopic anatomy of the major salivary glands of the ferret. *Acta Anat.* 98: 434-443.
- Poddar S, Jacob S (1978). Histology and mucosubstance hisochemistry of mongoose salivary glands. *Acta Anat.* 100: 545-556.
- Quintarelli G, Dellovo MC (1964). Activation of glycoprotein biosynthesis by testosterone propionate on mouse exorbital glands. *J. Histochem. Cytochem.* 13: 361-364.
- Reifel CW, Travill AA (1972). Structure and carbohydrate histochemistry of postnatal canine salivary glands. *Am. J. Anat.* 134: 377-394.
- Spicer SS, Duvenci J (1964). Histochemical characteristics of mucopolysaccharides in salivary and exorbital lachrymal glands. *Anat. Rec.* 149: 333-358.
- Weibel ER (1970). Stereological principles for morphometry in electron microscopic cytology. *Int. Rev. Cytol.* 276: 235-302.